

Anastomosis of nasal mucosal and lacrimal sac flaps in endoscopic dacryocystorhinostomy

Matteo Trimarchi · A. Giordano Resti · C. Bellini ·
M. Forti · M. Bussi

Received: 22 February 2009 / Accepted: 12 May 2009 / Published online: 5 June 2009
© Springer-Verlag 2009

Abstract Endoscopic dacryocystorhinostomy (DCR) is a well-established alternative to external approaches in the treatment of nasolacrimal canal obstruction. From July 2004 to December 2008, 92 endoscopic DCRs were performed on 88 patients at the Department of Otorhinolaryngology, San Raffaele Hospital, Milan. All patients were affected by chronic dacryocystitis with epiphora. Preoperative work-up included Jones tests, lacrimal pathways irrigation, nasal endoscopy, and imaging evaluation by computed tomography. The technique involved anastomosis of nasal mucosal, lacrimal sac flaps and a large bony ostium. A silicone tube was inserted in all patients that remained for a period of 3 months. The first endoscopic intervention was successful in 91.30% of patients. After a second revision endoscopic DCR, the overall success rate raised to 95.65%. Anastomosis of nasal mucosal between lacrimal sac flaps plays a key role in endoscopic DCR with a high success rate both in primary nasolacrimal obstructions and in revision cases.

Keywords Dacryocystorhinostomy (DCR) ·
Lacrimal sac · Endoscopy · Epiphora · Dacryocystitis

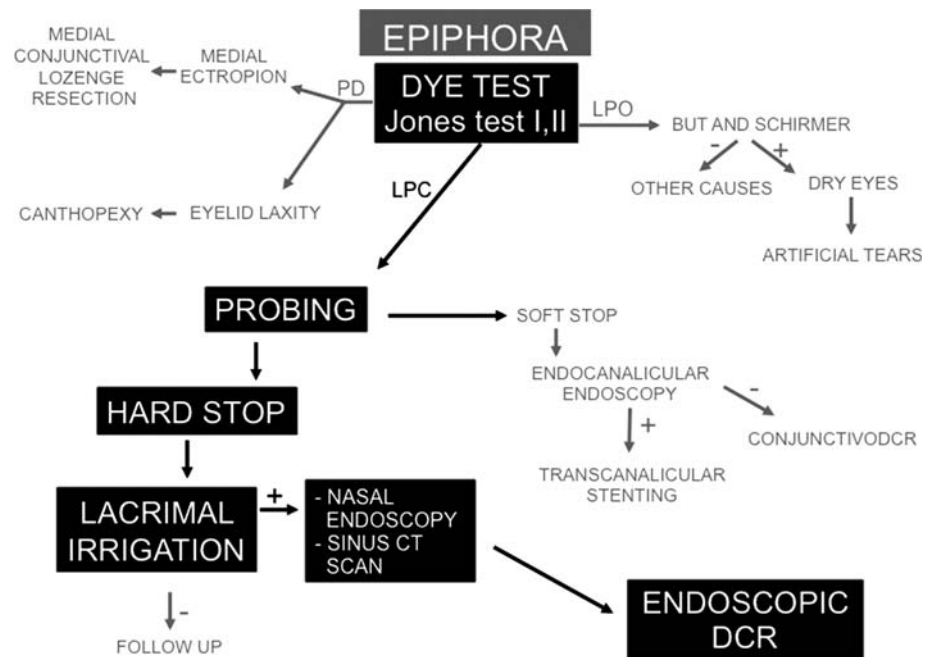
Introduction

The standard surgical procedure for nasolacrimal outflow tract obstruction is dacryocystorhinostomy (DCR) in which the lacrimal sac is connected directly to the nose to allow drainage of tears [1]. This technique is currently used by both ophthalmologists and ENT surgeons. The primary causes of lacrimal pathway obstruction include acute or chronic inflammation, trauma or congenital malformations. Patients generally present with epiphora, eyelid and lacrimal sac swelling, purulent secretion, blurred vision and facial pain. Dacryocystitis and recurrent conjunctivitis are typical. Although Caldwell [2] was the first to propose an endonasal approach in 1893, it was limited by the technology available at that time. Toti [3] is considered the father of DCR, and described for the first time, in 1904, an external procedure. With the advent of rigid nasal endoscopes which facilitated intranasal access to the lacrimal sac, an endoscopic approach became feasible and was first used clinically in the late 1980s [4]. An endoscopic procedure offers a well-established alternative to external DCR for the treatment of obstructions of the lacrimal pathway. The advantages of endoscopic DCR include avoidance of external scar formation, preservation of the pump mechanism of orbicularis muscle, improved hemostasis and decreased postoperative discomfort. The success rate of endoscopic procedure is comparable to that of a traditional, external approach, and also allows the surgeon to correct paranasal sinusitis, septal deviations or other nasal abnormalities. We present our clinical and

M. Trimarchi (✉) · C. Bellini · M. Bussi
Department of Otorhinolaryngology,
IRCCS San Raffaele Hospital,
Vita-Salute University,
via Olgettina 60, 20132 Milan, Italy
e-mail: trimarchi.matteo@hsr.it

A. Giordano Resti · M. Forti
Department of Ophthalmology,
IRCCS San Raffaele Hospital,
Vita-Salute University, Milan, Italy

Fig. 1 Diagnostic work-up for patients with epiphora. *LPO* lacrimal pathways open, *LPC* lacrimal pathways closed, *PD* pump defect



surgical experience on endoscopic DCR, discussing the surgical technique, results and follow-up of patients.

Materials and methods

From July 2004 to December 2008, 92 endoscopic DCRs were performed at the Department of Otorhinolaryngology, San Raffaele Hospital of Milan. Data were collected on 88 patients (19 male, 69 female). The average patient age was 56 years (range 5–84 years). After primary surgery, eight patients were affected by relapses. Of these, five underwent revision surgery.

In all cases, preoperative work-up (Fig. 1) was performed by an ophthalmologist and ENT specialists. The ophthalmologist begins with Jones tests 1 and 2 (Fig. 2). When lacrimal pathways are closed, the patient undergoes lacrimal probing and if a hard stop is found, lacrimal irrigation is performed. After lacrimal occlusion is verified, nasal endoscopy and imaging with computed tomography were carried out.

All procedures were performed under general anaesthesia with both an otorhinolaryngologist and ophthalmologist. To provide sufficient topical decongestion and vasoconstriction, the nose was packed with cotton pledgets soaked in 4% adrenaline, followed by submucosal injection of mepivacaine 20 mg/ml and adrenaline 1:200,000 over the proposed rhinostomy site.

The surgical technique consisted in the creation of an anastomosis between the nasal mucosa and the lacrimal sac (Fig. 3). A 30° nasal rigid endoscope was used. After the maxillary line was identified, we incised the nasal mucosa

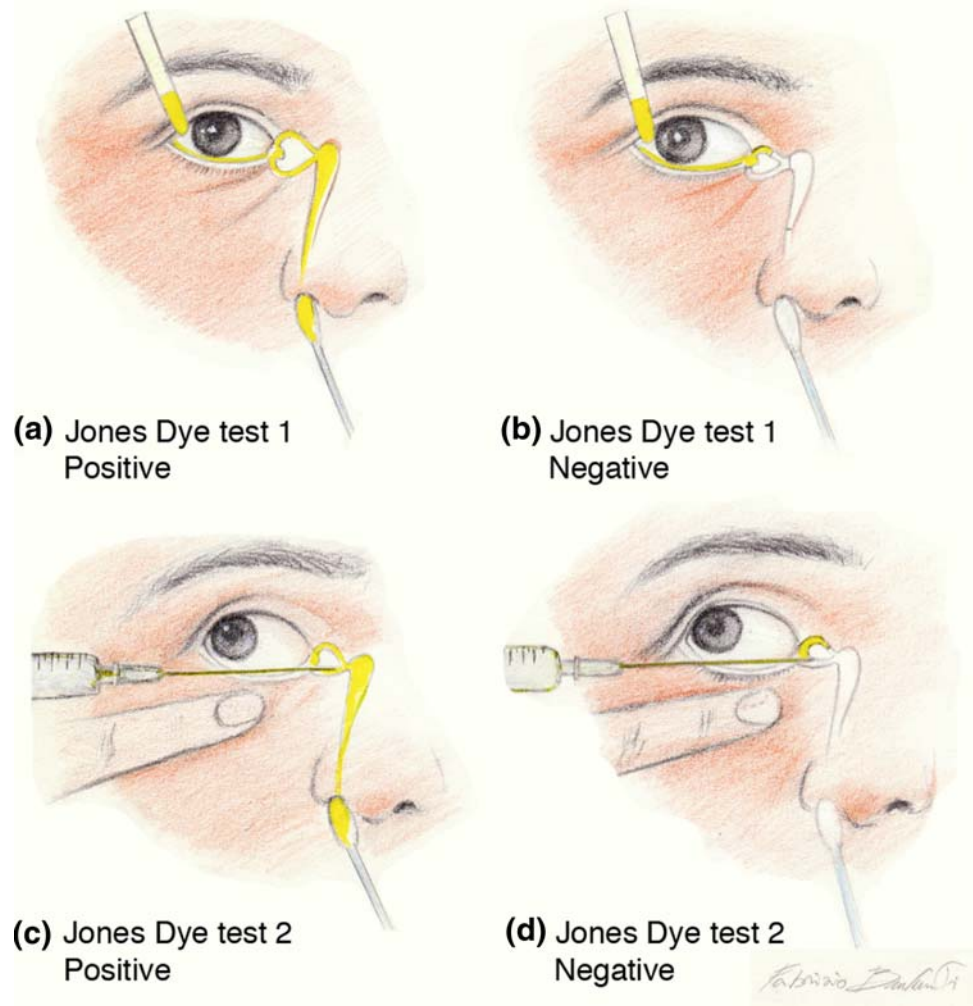
harvesting a posteriorly based muco-periosteal flap in order to expose the lacrimal bone. The mucosal incision started from the axilla of the middle turbinate and continued anteriorly for 5 mm before it took a cranio-caudally direction parallel to the maxillary line up to insertion of the inferior turbinate. Thus, incision continued about 8 mm posteriorly.

The bone was palpated to identify the junction between soft lacrimal bone and the hard bone of the frontal process. Removal of the soft lacrimal bone and the lower portion of the frontal process of the maxilla uncovered the central and inferior regions of lacrimal sac medial wall, which can avoid postoperative ostium stenosis. Next, the ophthalmologist introduced a Bowman's canalicular probe through the inferior punctum: the tip must be seen moving behind the sac wall and is used as a guide to make a vertical incision in the central portion of the medial sac wall. After making upper and lower releasing incisions, anterior and posterior flaps are created, harvesting a reverse "H" shape. The flaps can be rolled out and lie flat on the lateral nasal wall. On occasion, purulent material escaped due to sac incision.

The ophthalmologist then dilates the puncta and places a Catalano stent through the upper and lower puncta. The tube is then retrieved endonasally and a loop is made. The mucosal flap is now repositioned over the opened sac and is cut creating an L-shaped flap bordering the site of the new rhinostomy (Fig. 4). Ensuring contact between the lacrimal and nasal mucosa, first intention healing can be obtained.

The nose was not packed after surgery, except in one case in which the patient had significant bleeding. In this patient, the packing was removed on postoperative day 1. The silicone tube then remained in place for 3 months.

Fig. 2 Preoperative work-up. Instil one drop of fluorescein into the conjunctival sac (a). A cotton bud is placed in the inferior meatus. If fluorescein is detected after 5 min, the system is patent (positive primary Jones test). If no fluorescein is discovered, then the test is considered negative (b) and lacrimal stop can be functional or obstructive. Next, the excess fluorescein is washed from the conjunctival sac and syringe. If fluorescein is detected, then this shows that it had entered the sac and constitutes a positive secondary Jones test (c), and suggests functional obstruction of the nasolacrimal duct. If no dye is found on the cotton bud after syringing, this is considered a negative secondary Jones test since fluorescein had not entered the sac and, thus, the stenosis could be anywhere in the lacrimal pathway (d)



Follow-up assessment included lacrimal pathway irrigations and nasal endoscopy to evaluate anatomical patency (Fig. 5). Follow-up visits were performed on days 1 and 4, and once a week for the first month and consisted in removal of fibrin at the rhinostomy site. Subjective postoperative evaluation criteria included patient satisfaction, while objective criteria included persistence or disappearance of epiphora, recurrence of dacryocystitis and lacrimal patency by lacrimal irrigation and nasal endoscopy.

Postoperatively, all patients were treated with oral antibiotics, pain medication, intranasal saline spray, intranasal ointment applications and steroid eye drops that were applied at home for a 7-day period. Saline irrigations were continued until the rhinostomy site was completely healed.

Results

Considering the initial endoscopic procedure ($n = 92$), surgery was successful in 84 cases and patients no longer presented epiphora. Of these, 8 were revision cases after an

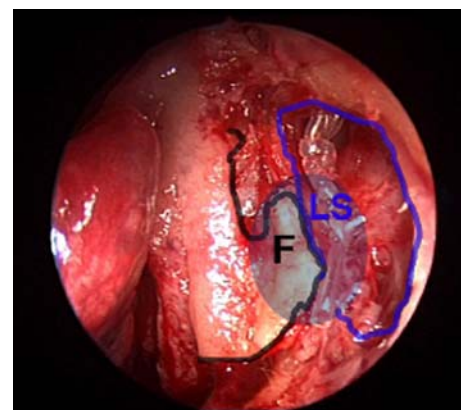


Fig. 3 Anastomosis between nasal mucosal flap (F) and lacrimal sac (LS)

external procedure and 76 were primary procedures. Thus, after first endoscopic surgery, eight patients were affected by relapses. The first success rate was thus 91.30%.

Postoperative visits demonstrated that lacrimal pathways were free at follow-up times ranging from 4 to 57 months

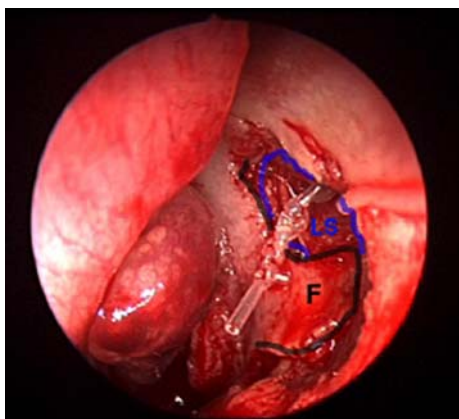


Fig. 4 Repositioning of the L-shaped mucosal flap (F) over the opened sac (LS)

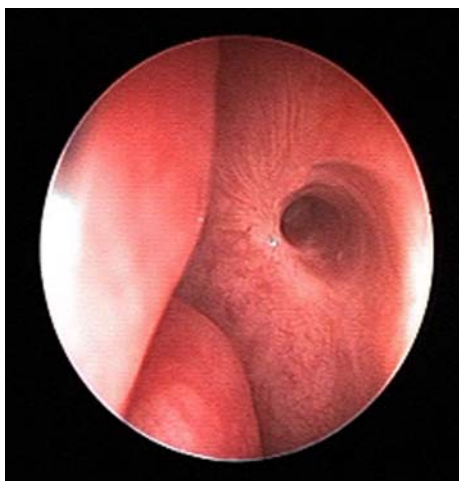


Fig. 5 Endoscopic control 4 years later

(mean 17 months). Of the eight cases that were classified as failures after the first endoscopic procedure, no patient was a revision case. Of these, three decided not to undergo further treatment and five underwent a second endoscopic DCR. After secondary endoscopic DCR, four procedures were successful, increasing the overall success rate to 95.65%. Only one patient underwent a third surgery, which failed. This patient was a woman who had been previously treated by radioiodine therapy for papillary thyroid cancer. Among the five patients who were treated twice, two were affected by acute dacryocystitis. In our cohort, four patients underwent bilateral treatment: three in the same procedure (one lacrimal pathway was touched-up and the other was treated for the first time) and one at different times.

All patients were affected by chronic dacryocystitis with epiphora. Four patients were treated during acute episodes of dacryocystitis. In 38 cases, we detected a mucopurulent secretion from lacrimal pathways. Concerning causes of nasolacrimal canal obstruction, in our series, we had one case of stenosis due to Wegener granulomatosis, one to

trauma and one secondary to removal of an inverted papilloma. One patient presented with lacrimal obstruction correlated with a benign neoplasm of the lacrimal sac (diagnosis of solitary fibrous tumour by histological examination).

Septoplasty was required in two DCRs for which an endoscopic technique was used. Five patients needed additional endoscopic surgery in conjunction with lacrimal surgery. Three of these patients were affected with concha bullosa, one with sinus polyposis and one with nasal synchia. In one case, lacrimal punctum stenosis was discovered that was treated with a three-cut punctoplasty by the ophthalmologist.

The mean operative time for primary DCR was about 40 min (range 28–65 min). Postoperative complications included eyelid oedema and bruise in three cases, which were treated with topical anti-inflammatory therapy. One patient presented myodesopsia in the treated eye in the immediate postoperative period and underwent evaluation by an ophthalmologist. In this patient, a visual acuity of 10/10 and a normal anterior segment were found. Upon ophthalmoscopic examination, since no pathological features were noted, a wait and see policy was adopted; after a few days, symptoms disappeared. Concerning long-term complications, in three cases, patients presented with nasal synchia that were treated under local anaesthesia.

Considering outcome criteria, there was a direct correlation between subjective and objective parameters. If anatomical patency is reached, in most cases, patients no longer reported epiphora and dacryocystitis, and were satisfied. There was only one patient in which a large patent DCR was achieved with persistence of epiphora. In this patient, Jones tests 1 and 2 were repeated during follow-up, and the former was negative and the latter positive. Thus, it was concluded that this patient also had a pump defect. Considering the history of the patient, it should be noted that canalicular endoscopy was performed before DCR.

Discussion

To establish correct diagnosis and management of nasolacrimal obstructions before surgery, in our opinion, patients require irrigation of the lacrimal system, Jones tests and a CT scan. Irrigation of the lacrimal pathways is an easy, safe and low cost examination that can lead to correct diagnosis. Although some authors [5] affirm that a CT scan should be reserved for trauma and malformations, we believe that it can be useful in the presence of nasolacrimal obstructions. CT scans allow visualization of the anatomy of the bone frame, and also detect the position of the uncinat process and its relationship with lacrimal bone and the lacrimal sac. Moreover, it permits knowledge of the position and

pneumatization of agger nasi. It can also reveal other sinus pathologies or nasal abnormalities. In the case of the benign neoplasms of the lacrimal sac, a CT scan can suggest involvement of lacrimal pathways. We present a flowchart for our patients in terms of diagnostic work-up and management (Fig. 1).

The success rates of endoscopic DCR reported in the literature range from 79.4 to 96% [6–12]. In our study, endoscopic DCR showed a success rate of 91.30% after the first surgery, with complete resolution of symptoms and an open pathway as evaluated by irrigations of the lacrimal system and nasal endoscopy. After a second surgery, a success rate of 95.65% was achieved.

In one patient, we performed three DCRs without success. This patient was previously treated with I(131) for thyroid cancer. Interestingly, the use of I(131) for thyroid carcinoma has been associated with a 3.4% incidence of documented nasolacrimal drainage obstruction [13]. We, therefore, hypothesize that the failure in this patient was due to altered healing caused by I(131). Regarding causes of failures, we observe that only two patients had acute episode of dacryocystitis. In our series, we found no correlation between causes of obstruction (such as Wegener granulomatosis, trauma, neoplasm of lacrimal sac, etc.) and failure. The same was true for additional surgery.

An endoscopic approach offers many advantages over traditional approaches, including less skin trauma and scar tissue formation, preservation of lacrimal pump function, reduction of intraoperative bleeding and better visualization of anatomical structures. In the present study, except for associated endoscopic procedures, the time required for primary surgical procedures was approximately 40 min, while for secondary procedures it was 35 min. Our surgical procedure includes the creation of an anastomosis between nasal mucosa and the lacrimal sac. The complete exposure of the sac, its marsupialization into the lateral nasal wall and the preservation of mucosa with fashioning of a mucosal flap allow the nasal and lacrimal mucosa to be apposed with first intention healing. The apposition between nasal and lacrimal mucosa and the recutting of an L-shaped mucosal flap bordering the opened sac ensure the patency of the new rhinostomy and also decrease the risk of granulations and scar tissue formation thus providing reproducible surgical results. The co-presence of an ophthalmologist is useful for both preoperative work-up and during surgery, helping to better understand practical aspects of the lacrimal pathways, as previously described.

Some authors have described the use of topical application of mitomycin-C within the marsupialized lacrimal sac during endoscopic procedures [4, 9, 14, 15]. This anti-metabolite, well-known for its antitumour activity, reduces scar formation and is generally considered a safe adjunct to endoscopic DCR. However, the use of agent is controversial

since, according to some authors, it increases the success rate both in primary and revision procedures [4] in some but not all procedures. Local instillation of mitomycin-C has no systemic side effects, although local side effects such as conjunctival irritation, excessive lacrimation and mild superficial punctate keratitis have been described [4]. For this reason, we do not use it for DCR.

To prevent obliteration of intranasal lacrimal sac ostium, many surgeons insert bi- or monocanalicular silicone tubes to stent the rhinostoma [16]. We use a bicanalicular stent known as a Catalano stent that is implanted for approximately 3 months before removal. Silicone tubing may cause formation of granulation tissue, infection and canalicular laceration. It can also become dislocated from the rhinostomy site and cause discomfort to patients. Nevertheless, the use of stenting and its duration is not well established. Some authors [5, 16–18] have described no differences in the success rate using a stent system. Stenting may also be contraindicated due to an increase in the occurrence of DCR stenosis [19]. We, however, routinely use a Catalano stent as it is easier to follow-up patients and to treat relapses as the ostium can be already identified.

Follow-up time is another crucial topic when interpreting the results of DCR. Endoscopic controls using a 30° rigid endoscope allow removal of granulation tissue, scars and nasal secretion at the rhinostomy site as well as irrigation of lacrimal pathways. Defined follow-up intervals are the easiest means of observing patients during the postoperative period and analyzing outcome. Moreover, a successful endoscopic DCR can become a failure if not adequately followed-up, and good surgical procedure is only part of successful DCR.

Conclusions

Endoscopic DCR is an efficacious method with a high success rate in both primary nasolacrimal obstructions and in revision surgery. The anastomosis between lacrimal and nasal flap is the most important aspect of the surgical procedure, is safe and provides consistent results. Lastly, we want to emphasize the important role of rigorous follow-up in preventing adhesions and obstruction of rhinostoma. Precise technique and assuring anatomical patency are keys to avoid surgical failure.

References

1. Tsirbas A, Davis G, Wormald PJ (2005) Revision dacryocystorhinostomy: a comparison of endoscopic and external techniques. *Am J Rhinol* 19(3):322–325
2. Caldwell G (1893) Two new operations for obstruction of the nasal duct, with preservation of the canaliculi, and with an

- incidental description of a new lacrimal probe. *Am J Ophthalmol* 10:189–193
3. Toti A (1904) Nuovo metodo conservatore di cura radicale delle suppurazioni croniche del sacco lacrimale (dacriocistorinostomia). *Clin Moderna* 10:385
 4. Selig YK, Biesman BS, Rebeiz EE (2000) Topical application of mitomycin-C in endoscopic dacryocystorhinostomy. *Am J Rhinol* 14(3):205–207. doi:[10.2500/105065800782102672](https://doi.org/10.2500/105065800782102672)
 5. Muscatello L, Giudice M, Spriano G, Tondini L (2005) Endoscopic dacryocystorhinostomy: personal experience. *Acta Otorhinolaryngol Ital* 25(4):209–213
 6. Hartikainen J, Antila J, Varpula M, Puukka P, Seppä H, Grénman R (1998) Prospective randomized comparison of endonasal endoscopic dacryocystorhinostomy and external dacryocystorhinostomy. *Laryngoscope* 108(12):1861–1866. doi:[10.1097/00005537-199812000-00018](https://doi.org/10.1097/00005537-199812000-00018)
 7. Pár I, Pliskvová I, Plch J (1998) Endoscopic endonasal dacryocystorhinostomy: indications, technique and results. *Cesk Slov Oftalmol* 54(6):387–391 Czech
 8. Cokkeser Y, Evereklioglu C, Er H (2000) Comparative external versus endoscopic dacryocystorhinostomy: results in 115 patients (130 eyes). *Otolaryngol Head Neck Surg* 123(4):488–491. doi:[10.1067/mhn.2000.105470](https://doi.org/10.1067/mhn.2000.105470)
 9. Liu D, Bosley TM (2003) Silicone nasolacrimal intubation with mitomycin-C: a prospective, randomized, double-masked study. *Ophthalmology* 110(2):306–310. doi:[10.1016/S0161-6420\(02\)01751-7](https://doi.org/10.1016/S0161-6420(02)01751-7)
 10. Zilelioğlu G, Uğurbaş SH, Anadolu Y, Akiner M, Aktürk T (1998) Adjunctive use of mitomycin C on endoscopic lacrimal surgery. *Br J Ophthalmol* 82(1):63–66. doi:[10.1136/bjo.82.1.63](https://doi.org/10.1136/bjo.82.1.63)
 11. Mäntynen J, Yoshitsugu M, Rautiainen M (1997) Results of dacryocystorhinostomy in 96 patients. *Acta Otolaryngol Suppl* 529:187–189. doi:[10.3109/00016489709124118](https://doi.org/10.3109/00016489709124118)
 12. Dolman PJ (2003) Comparison of external dacryocystorhinostomy with nonlaser endonasal dacryocystorhinostomy. *Ophthalmology* 110(1):78–84. doi:[10.1016/S0161-6420\(02\)01452-5](https://doi.org/10.1016/S0161-6420(02)01452-5)
 13. Burns JA, Morgenstern KE, Cahil KV, Foster JA, Jhiang SM, Kloos RT (2004) Nasolacrimal obstruction secondary to I(131) therapy. *Ophthal Plast Reconstr Surg* 20(2):126–129. doi:[10.1097/01.IOP.0000117340.41849.81](https://doi.org/10.1097/01.IOP.0000117340.41849.81)
 14. Lee TS, Woog JJ (2001) Endonasal dacryocystorhinostomy in the primary treatment of acute dacryocystitis with abscess formation. *Ophthal Plast Reconstr Surg* 17(3):180–183. doi:[10.1097/00002341-200105000-00006](https://doi.org/10.1097/00002341-200105000-00006)
 15. Camara JG, Bengzon AU, Henson RD (2000) The safety and efficacy of mitomycin C in endonasal endoscopic laser-assisted dacryocystorhinostomy. *Ophthal Plast Reconstr Surg* 16(2):114–118. doi:[10.1097/00002341-200003000-00005](https://doi.org/10.1097/00002341-200003000-00005)
 16. Smirnov G, Tuomilehto H, Teräsvirta M, Nuutinen J, Seppä J (2006) Silicone tubing after endoscopic dacryocystorhinostomy: is it necessary? *Am J Rhinol* 20(6):600–602. doi:[10.2500/ajr.2006.20.2955](https://doi.org/10.2500/ajr.2006.20.2955)
 17. Walland MJ, Rose GE (1994) The effect of silicone intubation on failure and infection rates after dacryocystorhinostomy. *Ophthalmic Surg* 25:597–600
 18. Unlu HH, Ozturk F, Nutlu C, Ilker SS, Tarhan S (2000) Endoscopic dacryocystorhinostomy without stents. *Auris Nasus Larynx* 27:65–71. doi:[10.1016/S0385-8146\(99\)00039-5](https://doi.org/10.1016/S0385-8146(99)00039-5)
 19. Allen K, Berlin AJ (1989) Dacryocystorhinostomy failure: association with nasolacrimal silicone intubation. *Ophthalmic Surg* 20:486–489